

Solanum anomalum leaf extract mitigated doxorubicin-induced kidney toxicity and oxidative stress in male rats

JUDE E. OKOKON^{1*}, JOHN AYOOLA ONUNKUN², MARTIN OSITA ANAGBOSO³, JOHN A. UDOBANG⁴

¹Department of Pharmacology and Toxicology, Faculty of Pharmacy, University of Uyo. Uyo 520103, Nigeria. Tel.: +234-8023453678,

*email: judeefiom@yahoo.com

²Department of Pharmacology and Toxicology, Faculty of Pharmacy, Madonna University. Elele Campus, P.M.B 05 Elele, Rivers State, Nigeria

³Department of Microbiology, Madonna University. Elele Campus, P.M.B 05 Elele, Rivers State, Nigeria

⁴Department of Clinical Pharmacology and Therapeutics, Faculty of Basic Clinical Sciences, University of Uyo. Uyo 520103, Nigeria

Manuscript received: 12 March 2024. Revision accepted: 2 July 2024.

Abstract. Okokon JE, Onunkun JA, Anagboso MO, Udobang JA. 2024. *Solanum anomalum* leaf extract mitigated doxorubicin-induced kidney toxicity and oxidative stress in male rats. *Asian J Nat Prod Biochem* 22: 59-66. *Solanum anomalum* Thonn. ex Schumach (family Solanaceae) is a shrub whose leaves are used locally to treat various diseases. Evaluation of the antidotal activity of leaf extract of *S. anomalum* was carried out to ascertain its uses in traditional medicine. The leaf extract (70-210 mg/kg) of *S. anomalum* was investigated for nephroprotective activity against doxorubicin-induced kidney toxicity in rats. Kidney function parameters, kidney histology, and kidney oxidative stress markers were used to assess the kidney protective effect of the extract. The leaf extract (70-210 mg/kg) significantly ($p < 0.05-0.01$) reduced the levels of creatinine, urea, and electrolytes that were elevated by doxorubicin. Also, the MDA level elevated by doxorubicin was reduced by the extract co-administration, while the levels of GSH, GST, SOD, GPx, and CAT that were decreased by doxorubicin were significantly ($p < 0.01$) elevated by the leaf extract. Histology of the kidney sections of extract-treated animals showed reductions in the pathological features compared to the organotoxic-treated animals. The chemical pathological changes were consistent with histopathological observations, suggesting marked nephroprotective potential. The anti-toxic effect of this plant may, in part, be mediated through the plant's chemical constituents. *S. anomalum* possesses anti-toxicant properties that can be exploited in treating doxorubicin-related toxicities.

Keywords: Doxorubicin, oxidative stress, renoprotective, *Solanum anomalum*

INTRODUCTION

Doxorubicin is an anthracycline glycoside antibiotic that possesses a potent and broad-spectrum antitumor activity against various human solid tumors and hematological malignancies (Calabresi and Chamber 1990). However, due to its diverse toxicities, its use in chemotherapy has been limited, including cardiac, hepatic, hematological, and testicular toxicity (Yilmaz et al. 2006). The semiquinone form of doxorubicin is a toxic, short-lived metabolite that initiates a cascade of reactions when it interacts with molecular oxygen, producing Reactive Oxygen Species (ROS). ROS generation, inflammatory processes, and lipid peroxidation have been suggested to be responsible for doxorubicin-induced cardio, hepatic, and nephrotoxicity (Kalender et al. 2005; Injac et al. 2009). It has been proposed that DOX-semiquinone, an unstable metabolite of DOX, reacts with O₂, producing H₂O₂ and O₂⁻ (superoxide). In addition, DOX enhances the activity of extramitochondrial oxidative enzymes such as NADPH and xanthine oxidases and also interferes with mitochondrial iron export, resulting in ROS formation (Bachur et al. 1979). These free radicals attack the cell's membranes and cause organ dysfunction.

Chronic Kidney Disease (CKD) contributes significantly to the development and progression of kidney failure, cardiovascular disease, and premature death (Levey

et al. 2007). Studies have reported that about 1.75 million patients worldwide receive renal replacement therapy through dialysis regularly. This figure is on the increase, and the estimated mortality in patients with Acute Kidney Injury (AKI) was 23.9% in adults and 13.8% in children (Susantitaphong et al. 2013). Previous studies reported that about 10% of the world's population is affected by CKD (Jha et al. 2013) due to increased risk factors such as obesity and diabetes mellitus, among others. Thus, an increased number of patients with CKD has been reported worldwide, and an estimated 843.6 million individuals worldwide were reported to be affected by CKD in 2017 (Jager et al. 2019). The Global Burden of Disease (GBD) reports indicated that CKD has emerged as one of the leading causes of death the world over (GBD 2013 Mortality and Causes of Death Collaborators 2015; Rhee and Kovesdy 2015), although there is a decline in patient mortalities with End-Stage Kidney Disease (ESKD) (Saran et al. 2020). Also, there was an increase of 41.5% in the global all-age mortality rate attributed to CKD between 1990 and 2017 (GBD 2020). About 36.8 million Nigerians (23%) have been estimated to suffer from kidney disease (Ebun 2013), which means that one in seven Nigerians is suffering from some kidney disorder.

Considering the high cost of management of kidney diseases, especially the burden of the high cost of dialysis and kidney transplants in Nigeria and many other

developing countries of the world, the search for an alternative treatment strategy is therefore inevitable. Plants provide a rich reservoir of natural therapeutic compounds that are affordable, readily available, and have less toxic effects. Investigation of plants with kidney protective potentials can lead to the discovery of active compounds that can serve as alternatives to currently available orthodox medicines which are costly and associated with many toxic effects (Okokon et al. 2022a).

Solanum anomalum Thonn. ex Schumach, a plant whose leaves and fruits are used medicinally and nutritionally, is commonly grown in Western and Eastern Africa sub-regions. Its plant parts are utilized locally to treat diabetes, gastrointestinal disorders, infections, inflammation, and pains (Bukanya and Hall 1988; Burkill 2000; Offor and Ubengama 2015). Many studies have been reported on their fruits and leaves hypoglycemic and antidiabetic activities (Offor and Ubengama 2015; Okokon et al. 2022a); in vivo and in vitro antiplasmodial (Okokon et al. 2016, 2017a); anti-edema (Okokon et al. 2017b); antioxidant and antiulcer (Okokon et al. 2019a); anticonvulsant and depressant (Okokon et al. 2019b); analgesic (Okokon et al. 2020) and antidiarrhoeal (Udobang et al. 2022). Moreover, the leaves' phytochemical constituents such as alkaloids, flavonoids, saponins, tannins, diosgenin, a diosgenin glycoside (25(R)-diosgenin-3-O- α -L-rhamnopyranosyl-(1 \rightarrow 4)- β -D-glucopyranoside, uracil, 5-methyluracil, 1-octacosanol, and octacosane have been reported (Okokon et al. 2016, 2022b). In this study, we report the renoprotective activity of the leaf extract against doxorubicin-induced kidney toxicity and oxidative stress.

MATERIALS AND METHODS

Plants collection

Fresh leaves of *S. anomalum* were collected from compounds in the Uruan area, Akwa Ibom State, Nigeria, in August 2022. Next, a taxonomist from the Department of Botany and Ecological Studies, University of Uyo, Uyo, Nigeria, identified and authenticated the plant's leaves. The herbarium specimen was deposited at the Department of Pharmacognosy and Natural Medicine Herbarium, University of Uyo (UUH.75a).

Extraction

Fresh leaves of *S. anomalum* were washed, cut into smaller pieces, and dried under shade for two weeks. The leaves were further pulverized to powder using an electric grinder. The powdered leaves material (1.5 kg) was macerated in 50% ethanol (7.5 L) for 72 hours at room temperature (28 \pm 2°C). Thereafter, the soaked leaves powder was filtered, and the liquid filtrate was concentrated and evaporated to dry in vacuo 40°C using a rotary evaporator (BuchiLab, Switzerland). The extract was stored in a refrigerator at -4°C until used for the proposed experiments (Okokon et al. 2015).

Animals

Albino Wistar rats (120-135 g) of either sex were used for these experiments. They were obtained from the Department of Pharmacology and Toxicology Animal House, Madonna University, Elele, Rivers State. All animals were well acclimatized having been kept in clean standard polypropylene cages with laboratory-grade pine shavings as beddings, contained in well-ventilated house and maintained under standard conditions (temperature: 25 \pm 3°C; photoperiod: 12-h natural light and 12-h dark cycle; humidity: 35-60 %) and fed on regular pellets (Guinea feed) and water ad libitum.

Experimental design

This study used a repeated dose model earlier described by Olorundare et al. (2020), which lasted for 14 days. Group I rats, the untreated control, were orally pretreated with distilled water at 10 mL/kg/day. Group 2 rats were given normal saline (10 mL/kg/day) but equally treated with 2.5 mg/kg of doxorubicin hydrochloride (@Celondoxily Injection 50, CELON Laboratories PVT. Limited, India) dissolved in 0.9% normal saline for 14 days on alternate days. Groups 3-5 rats were orally pretreated respectively with 70 mg/kg/day, 140 mg/kg/day, and 210 mg/kg/day of *S. anomalum* leaf extract dissolved in distilled water 2 hours before treatment with 2.5 mg/kg of doxorubicin in 0.9% normal saline administered intraperitoneally on alternate days for 14 days, respectively. Group 6 rats, the positive control group, were equally pretreated with 20 mg/kg/day of Vitamin C two hours before treatment with 2.5 mg/kg of doxorubicin in 0.9% normal saline administered intraperitoneally on alternate days for 14 days.

Blood sample collection

On the last day of the study (day 14), the rats were weighed and fasted overnight but were allowed access to drinking water ad libitum. Rats were sacrificed under light inhaled diethyl ether anesthesia, and whole blood samples were collected directly from the heart by cardiac puncture into plain sample bottles. Blood samples were carefully collected with fine 21G needles and 5 mL syringes without damaging the heart tissues. Finally, the rats' kidneys were identified, harvested, and weighed.

Kidney function test

The following biochemical parameters such as electrolyte levels (Na, K, Cl, and HCO₃), creatinine, and blood urea, were assayed as kidney function markers using diagnostic kits at the Chemical Pathology Department of the University of Port Harcourt Teaching Hospital.

Oxidative stress markers

The antioxidant enzyme assays were performed on kidney homogenates of rats used in this study. These oxidative stress markers assessed the extract's antioxidative stress potentials.

Preparation of renal homogenate

The kidneys were removed in each rat, and one kidney was fixed in 10% formaldehyde for histological processes. At the same time, the other kidney used for oxidative marker assays was dissected free from connective tissue and surrounding fat. The kidneys were longitudinally sectioned, and the renal cortex was separated and kept at -8°C. Subsequently, the renal cortex was homogenized in cold potassium phosphate buffer (0.05M, Ph 7.4). The renal cortical homogenates were centrifuged at 5,000 rpm for 10 min at 4°C; the obtained supernatant determines the superoxide dismutase (SOD) (Marklund and Marklund 1974), catalase (CAT) (Sinha 1972), glutathione peroxidase (GPx) (Lawrence and Burk 1976), reduced glutathione (GSH) (Ellman 1959) and malondialdehyde (MDA) content (Esterbauer and Cheeseman 1990).

Histopathological studies

The kidneys of the animals that were surgically removed and fixed in 10% formaldehyde were processed and stained with hematoxylin and eosin (H&E) (Drury and Wallington 1980), according to standard procedures at the Department of Chemical Pathology, University of Port Harcourt Teaching Hospital, Port Harcourt. Morphological changes were observed and recorded in the excised organs of the sacrificed animals. Histologic pictures were taken as micrographs.

Statistical analysis

Data obtained from this work were analyzed statistically using ANOVA (one-way) followed by a post-test (Tukey-Kramer multiple comparison test). Differences between means were considered significant at a 5% significance level, i.e., $p \leq 0.05$.

RESULTS AND DISCUSSION

The effect of leaf extract of *Solanum anomalum* on kidney weights and kidney function parameters of doxorubicin-induced kidney injury in rats

Treatment of rats with doxorubicin (2.5 mg/kg i.p) on alternate days for 14 days caused significant ($p < 0.01-0.001$) elevation of serum urea, creatinine, and electrolytes (K^+ , Na^+ , Cl^- and HCO_3^-) levels when compared to normal control. Standard reference values for normal wistar rats are; creatinine (0.2 -0.7 mg/dL), urea (11-25 mg/dl), Na (138-155 mMol/L), K (4.6-6.0 mMol/L), HCO_3^- (22.8-31.1

mEq/L) (Loeb and Quimby 1999). The values of the kidney function parameters of the normal rats in this study were within the standard range, while those of doxorubicin only-treated group were elevated above the standard range. These increased levels of serum urea, creatinine, and electrolytes were significantly ($p < 0.05-0.001$) reduced following concomitant treatment of the rats with vitamin C and leaf extract of *S. anomalum* (70-210 mg/kg) with doxorubicin though in a non-dose-dependent fashion (Table 1). Similarly, administration of doxorubicin (2.5 mg/kg i.p) to rats on alternate days for 14 days caused significant ($p < 0.05$) reduction of kidney weights of rats when compared to normal control group. Co-administration of leaf extract of *S. anomalum* with doxorubicin reversed these weight losses to near normal (Figure 1)

Effect of leaf extract on kidney oxidative stress markers

Administration of doxorubicin (2.5 mg/kg i.p) on alternate days for 14 days significantly ($p < 0.05-0.001$) caused decreases in kidney antioxidant enzymes activities (SOD, GPx, CAT) and GSH levels when compared to control. The MDA level was also elevated by doxorubicin treatment. However, concomitant administration of leaf extract of *S. anomalum* (70-210 mg/kg) with doxorubicin for 14 days caused marked significant ($p < 0.05-0.01$) elevation of the enzymatic and non-enzymatic endogenous antioxidants in the treated rat's groups when compared to the organotoxic groups. The treatment also caused a significant ($p < 0.001$) reduction in the level of MDA of the treated rats when compared to organotoxic control (Figures 2,3,4,5,6).

Effect of extract on the histology of kidney of rats

The histological sections of rat kidneys treated with distilled water showed normal glomeruli and tubules. However, sections of the kidneys of rats treated with doxorubicin (2.5 mg/kg) alone showed microvesicles in the tubular lining cells and normal glomeruli. Kidney sections of rats treated with 70 and 140 mg/kg of *S. anomalum* leaf extract and doxorubicin depicted normal glomeruli, and the tubules lined by anucleate epithelial cells with increased eosinophilia that sloughed into the lumen of the tubules. Rats treated with 210 mg/kg of *S. anomalum* leaf extract and doxorubicin had kidney sections with normal glomeruli. At the same time, the kidney sections of rats treated with 40 mg/kg of vitamin C and doxorubicin showed normal glomeruli (Figure 7.A-F).

Table 1. Effect of *Solanum anomalum* leaf extract on renal function parameters of rats with doxorubicin-induced kidney toxicity

Treatment	Dose (mg/kg)	Urea (mMol/L)	Creatinine (μ mol/L)	Chloride (mMol/L)	Potassium (mMol/L)	Sodium (mMol/L)	Bicarbonate (mMol/L)
Normal control	-	4.21±1.41	81.66±2.53	60.0±0.06	3.00±0.20	121.3±1.33	22.00±0.81
Doxorubicin	2.5	14.16±0.44 ^d	263.33±6.67 ^d	73.33±1.33 ^d	5.50±0.28 ^d	158.66±2.96 ^d	30.66±0.66 ^d
Vitamin C+DOX	20	4.93±0.43 ^c	99.0±9.00 ^c	70.66±2.66	4.13±0.16 ^b	124.66±4.66 ^b	22.66±1.66 ^a
Extract+DOX	70	5.03±0.32 ^c	104.66±5.04 ^c	65.33±2.33	3.16±0.08 ^c	121.33±2.33 ^b	25.0±1.00
	140	5.73 ±0.39 ^c	115.0±10.00 ^c	68.0±1.00	3.73±0.23 ^b	129.66±1.66 ^a	24.0±2.00 ^a
	210	5.00±0.23 ^c	98.66±5.66 ^c	79.0±1.04 ^d	4.36±0.26 ^a	137.33±7.33	22.33±1.33 ^a

Note: Data is expressed as MEAN ± SEM, Significant at ^d $p < 0.001$ compared to normal control; ^a $p < 0.05$, ^b $p < 0.01$, ^c $p < 0.001$ when compared to control (n = 6)

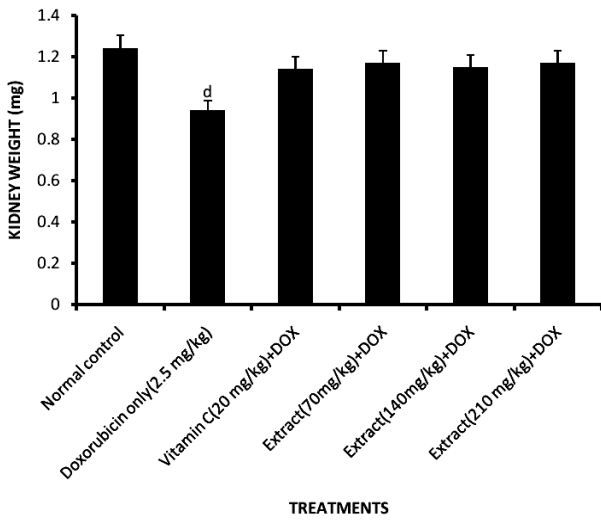


Figure 1. Effect of *S. anomalum* leaf extract on kidney weights of rats with doxorubicin-induced toxicity. Data is expressed as MEAN ± SEM, Significant at ^dp<0.001 compared to normal control when compared to control. (n=6). DOX: Doxorubicin

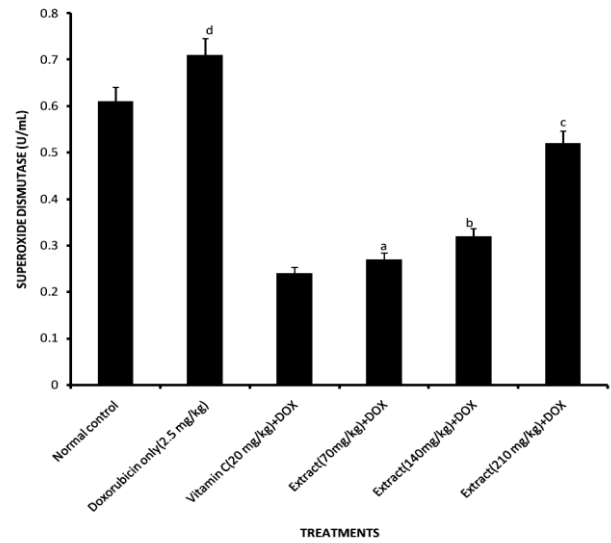


Figure 2. Effect of *S. anomalum* leaf extract on kidney superoxide dismutase levels of rats with doxorubicin-induced toxicity. Data is expressed as MEAN ± SEM, Significant at ^dp<0.001 compared to normal control; ^ap<0.05, ^bp< 0.01, ^cp< 0.001 when compared to control. (n = 6). DOX: Doxorubicin

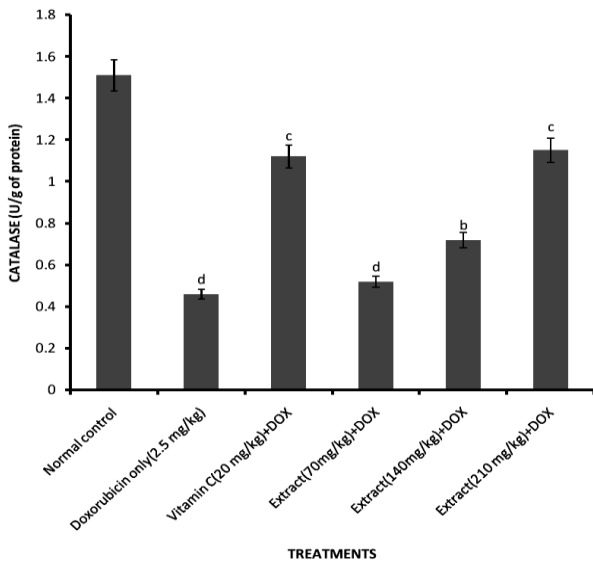


Figure 3. Effect of *S. anomalum* leaf extract on kidney catalase levels of rats with doxorubicin-induced toxicity. Data is expressed as MEAN ± SEM, Significant at ^dp<0.001 compared to normal control; ^ap<0.05, ^bp< 0.01, ^cp< 0.001 when compared to control. (n=6). DOX: Doxorubicin, N.S: Not significant

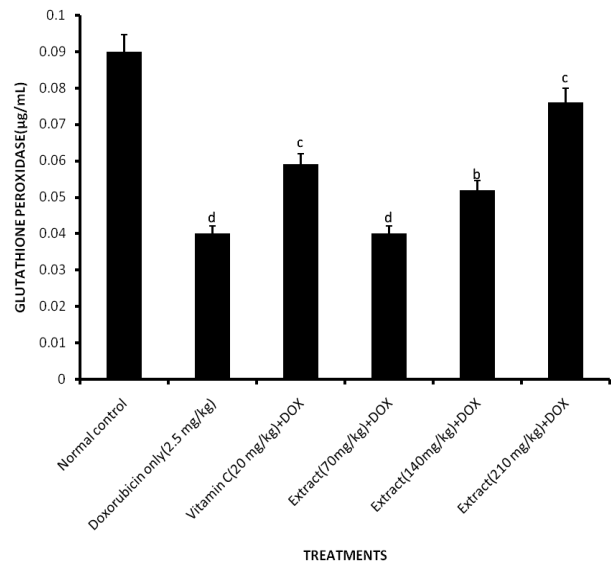


Figure 4. Effect of *S. anomalum* leaf extract on kidney glutathione peroxidase levels of rats with doxorubicin-induced toxicity. Data is expressed as MEAN ± SEM, Significant at ^dp<0.001 compared to normal control; ^ap<0.05, ^bp< 0.01, ^cp< 0.001 when compared to control. (n = 6). DOX: Doxorubicin

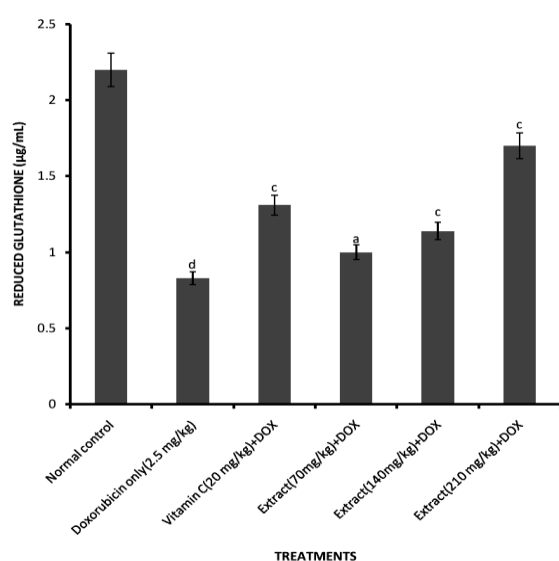


Figure 5. Effect of *S. anomalum* leaf extract on kidney reduced glutathione levels of rats with doxorubicin-induced toxicity. Data is expressed as MEAN \pm SEM, Significant at ^d $p < 0.001$ compared to normal control; ^a $p < 0.05$, ^b $p < 0.01$, ^c $p < 0.001$ when compared to control. (n = 6). DOX: Doxorubicin

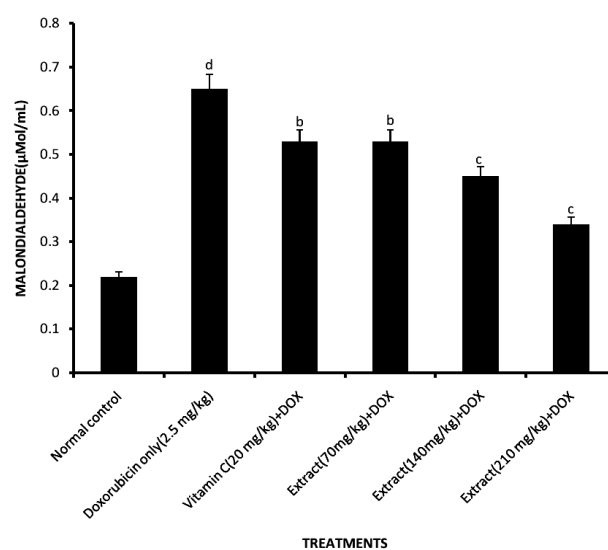


Figure 6. Effect of *S. anomalum* leaf extract on kidney malondialdehyde levels of rats with doxorubicin-induced toxicity. Data is expressed as MEAN \pm SEM, Significant at ^d $p < 0.001$ compared to normal control; ^a $p < 0.05$, ^b $p < 0.01$, ^c $p < 0.001$ when compared to control. (n = 6). DOX: Doxorubicin

Discussion

This work was designed to investigate the effect of leaf extract of *S. anomalum* on doxorubicin-induced liver toxicity in rats to confirm the folkloric claim of its antidotal activity. In this study, doxorubicin administration was found to have caused an elevation of serum urea (70.26%), creatinine (68.98%), and electrolytes (K^+ , Na^+ , Cl^- and HCO_3^-) levels (45.45, 23.54, 18.17 and 28.24% respectively) when compared to normal control. These values were observed to be above the standard reference values ranges for wistar rats; creatinine (0.2-0.7 mg/dL), urea (11-25 mg/dl), Na (138-155 mMol/L), K (4.6-6.0 mMol/L), HCO_3^- (22.8-31.1 mEq/L) (Loeb and Quimby 1999), which is an indication of a serious injury to the kidney. The values of the kidney function parameters of the normal rats in this study as well as those of extract-treated groups were within the standard range. This finding is consistent with an earlier report by Rajasekaran (2019), in which significant elevations were also reported. It is well documented that kidney injury is indicated by an increase in serum levels of creatinine and urea (Lakshmi and Sudhakar 2010) as well as an increase in serum levels of Na, K, Cl, and bicarbonate (James and Mitchel 2006). However, these increases were reduced significantly by the co-administration of leaf extract of *S. anomalum*.

Doxorubicin is reported to cause nephrotoxicity via oxidative stress as free radicals formed caused tubular atrophy and increased glomerular capillary permeability. Nephrotoxicity by doxorubicin can also result from lipid peroxidation and biological macromolecule damage by iron-dependent oxidative damage (Mohan et al. 2010). Degenerative changes in the kidney depend on the

cumulative dose and duration of treatment, as doxorubicin metabolites are partly excreted from the kidney. Another mechanism for renal injury is the conversion of DOX to semiquinone free radical by NADPH-cytochrome P-450, which generates hydroxyl radical and superoxide anion, and causes lipid peroxidation (Rashid et al. 2013). The reduction of urea, creatinine, and electrolyte levels by the leaf extract in this study results from the free radical scavenging potentials of the extract, thereby protecting the kidney against oxidative stress by free radicals generated by doxorubicin. This result corroborates previously reported nephroprotective potential of the leaf extract of *S. anomalum* against alloxan-induced kidney injury by Etuk et al. (2023a) and also agrees with Mohan et al. (2010), who reported significant nephroprotection of *Solanum torvum* against doxorubicin-induced kidney toxicity. Phytochemical compounds such as torvanol A, 3, 4-trimethyl triacontane, octacosanyltriacontanoate, 5-hexatriacontanone, triacontanol, 3-tritriacontanone, tetratriacontanoic acid, sitosterol, stigmasterol, campesterol, neochlorogenin 6-O- β -D-quinovopyranoside, neochlorogenin 6-O- β -D-xylopyranosyl-(1 \rightarrow 3)- β -D-quinovopyranoside, neochlorogenin 6-O- α -L-rhamnopyranosyl-(1 \rightarrow 3)- β -D-quinovopyranoside, solagenin 6-O- β -D-quinovopyranoside, solagenin 6-O- α -L-rhamnopyranosyl-(1 \rightarrow 3)- β -D-quinovopyranoside, isoquercetin, rutin, kaempferol and quercetin have been isolated and identified from the leaves of *S. torvum* (Mahmood et al. 1983; Yuan-Yuan et al. 2011). Some of these compounds have also been identified and isolated from *S. anomalum* thereby laying credence to the observed nephroprotective activity in this study.

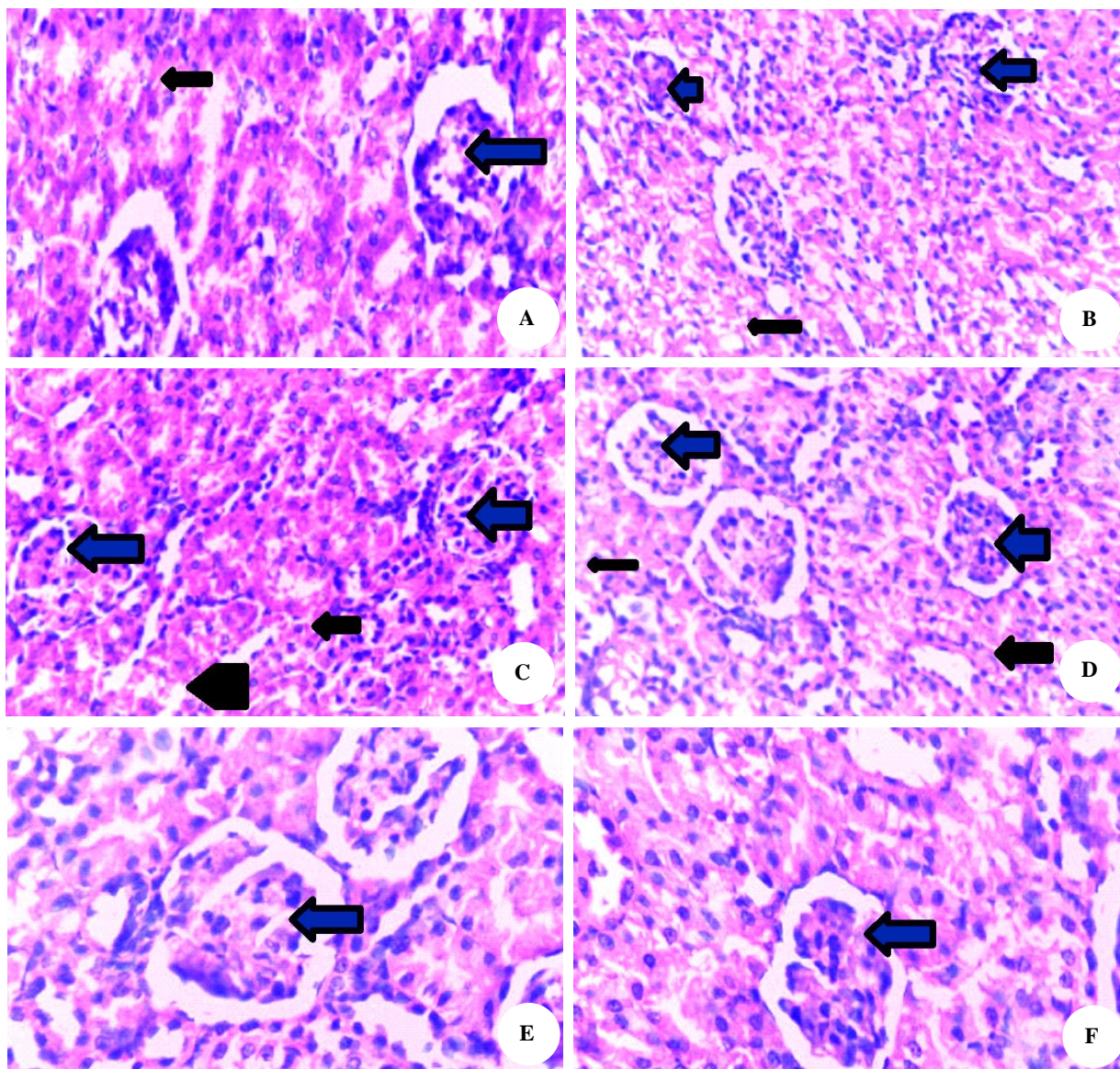


Figure 7. Histological section of rat kidneys. A. Treated with distilled water showing normal glomeruli (*blue*) and normal tubulus (*black*), B. Treated with doxorubicin (2.5 mg/kg) alone showing microvesicles in the tubular lining cells (*black*) and normal glomeruli (*blue*), C. Treated with 70 mg/kg of *S. anomalum* leaf extract and doxorubicin showing section of kidney with normal glomeruli (*blue*), the tubules (*black*) are lined by anucleate epithelial cells with increased eosinophilia that sloughing into the lumen of the tubulus, D. Treated with 140 mg/kg of *S. anomalum* leaf extract and doxorubicin showing section of kidney with normal glomeruli (*blue*) and the tubulus (*black*) are lined by anucleate epithelial cells with increased eosinophilia that sloughing into the lumen of the tubulus, E. Treated with 210 mg/kg of *S. anomalum* leaf extract and doxorubicin showing section of kidney with normal glomeruli (*blue*), F. Treated with 40 mg/kg of vitamin C and doxorubicin showing section of kidney with normal glomeruli (*blue*)

Moreover, Offor et al. (2021) reported significant protection of the kidney against Lead-induced kidney injury by fruit extract of this plant, further supporting and confirming the nephroprotective activity of *S. anomalum*. The observed nephroprotective activity of the leaf extract against the effect of free radicals generated by doxorubicin is due to antioxidant activities of the phytoconstituents (Okokon et al. 2019a) such as diosgenin (Kanchan et al. 2016), 1-octacosanol and octacosane (Sengupta et al. 2018; Leng et al. 2020; Rhetso et al. 2020), squalene (Gunes 2013; Micera et al. 2020), β -sitosterol (Gupta et al. 2011; Baskar et al. 2012) and phenolic compounds in the leaf extract.

This study further revealed that administration of doxorubicin (2.5 mg/kg, i.p) on alternate days for 14 days to rats caused significant decreases ($p < 0.05$) in levels of enzymatic and non-enzymatic endogenous antioxidants (GSH, SOD, CAT, GPX, and GSH) when compared to control, while the MDA level was elevated. Lipid peroxidation is a marker of oxidative stress, and elevations in the amount of malondialdehyde (MDA), a lipid peroxidation product, have been reported following doxorubicin treatment (Rashid et al. 2013; Rehman et al. 2014; Khames et al. 2019); this trend was also observed in this study. Concomitant administration of leaf extract *S.*

anomalum (70-210 mg/kg) with doxorubicin caused significant ($p < 0.05-0.001$) non-dose-dependent elevation in the levels of the antioxidant enzymes (SOD, CAT, GPX) when compared to control. Similarly, the GSH level was significantly ($p < 0.001$) elevated after treatment with the extract compared to the control. Furthermore, administration of the leaf extract results in significant ($p < 0.05-0.01$) reductions in the level of MDA of the extract-treated rats. It has been documented that DOX inhibits the activities of endogenous enzymatic and non-enzymatic antioxidants, as shown in this study. So, an imbalance between ROS generation and neutralization leads to oxidative stress and injury to the kidney (Abushouk et al. 2017, 2019; Abdel-Daim et al. 2017). The reduced MDA level caused by the administration of the leaf extract may have resulted from a reduction in lipid peroxidation and generation of free radicals, which might have been scavenged by the phytoconstituents present in this extract, revealing the antioxidative stress potentials of the leaf extract and hence the protective effect on the kidney as was observed in this study and reported previously by Etuk et al. (2023b).

This study revealed histological findings that the kidneys of rats treated with doxorubicin (2.5 mg/kg) alone showed pathological signs of injury, which were seen as degenerated microvesicles in the tubular lining cells, among others. However, co-administration of *S. anomalum* leaf extract and doxorubicin reduced the toxic effects of the doxorubicin as normal glomeruli devoid of pathological signs were seen in the kidney sections of the extract-treated rats examined. This further confirms the leaf extract's nephroprotective potential, which may have been exerted through its phytochemical constituents' antioxidant and antioxidative stress activities.

In conclusion, the findings of this study show that the leaf extract of *S. anomalum* (70-210 mg/kg) has the potential to counteract the detrimental effect of doxorubicin on the kidney. This activity can be attributed to its phytochemical constituents' antioxidant and antioxidative stress activities. Thus, the leaf can alleviate and/or prevent doxorubicin-induced nephrotoxicity.

ACKNOWLEDGEMENTS

The authors are grateful to the management of Madonna University, Elele Campus, Nigeria, for providing an enabling environment and facilities to complete this work.

REFERENCES

- Abdel-Daim MM, Kilany OE, Khalifa HA, Ahmed AAM. 2017. Allicin ameliorates doxorubicin-induced cardiotoxicity in rats by suppressing oxidative stress, inflammation and apoptosis. *Cancer Chemother Pharmacol* 80 (4): 745-753. DOI: 10.1007/s00280-017-3413-7.
- Abushouk AI, Ismail A, Salem AMA, Afifi AM, Abdel-Daim MM. 2017. Cardioprotective mechanisms of phytochemicals against doxorubicin-induced cardiotoxicity. *Biomed Pharmacother* 90: 935-946. DOI: 10.1016/j.biopha.2017.04.033.
- Abushouk AI, Salem AMA, Saad A, Afifi AM, Afify AY, Afify H, Salem HSE, Ghanem E, Abdel-Daim MM. 2019. Mesenchymal stem cell therapy for doxorubicin-induced cardiomyopathy: Potential mechanisms, governing factors, and implications of the heart stem cell debate. *Front Pharm* 10: 635. DOI: 10.3389/fphar.2019.00635.
- Bachur NR, Gordon SL, Gee MV, Kon H. 1979. NADPH-cytochrome P450 reductase activation of quinone anticancer agents to free radicals. *Proc Natl Acad Sci USA* 76: 954-957. DOI: 10.1073/pnas.76.2.954.
- Baskar AA, Al Numair KS, Paulraj MG, Alsaif MA, Muamar M, Ignacimuthu S. 2012. β -sitosterol prevents lipid peroxidation and improves antioxidant status and histoarchitecture in rats with 1,2-dimethylhydrazine-induced colon cancer. *J Med Food* 15 (4):335-43. DOI: 10.1089/jmf.2011.1780.
- Bukenya ZR, Hall JB. 1988. *Solanum* (Solanaceae) in Ghana. *Bothalia* 18 (1): 79-88. DOI: 10.4102/abc.v18i1.983.
- Burkhill HM. 2000. *The Useful Plants of West Tropical Africa*. 2nd Edition. Volume 5, Families S–Z, Addenda. Royal Botanic Gardens, Kew, United Kingdom.
- Calabresi P, Chabner BA. 1990. *Chemotherapy of neoplastic diseases*. In: Gilman AG, Rall TW, Nies AS, Taylor P (eds). *The Pharmacological Basis of Therapeutics*. Pergamon Press Inc, New York.
- Drury RA, Wallington EA. 1980. *Carleton's Histological Techniques*. 5th Edition, Oxford University Press, New York.
- Ebum RA. 2013. Newsletter during Gastroenterology Week, Lagos.
- Ellman GL. 1959. Tissue sulfhydryl groups. *Arch Biochem Biophys* 82: 70-77. DOI: 10.1016/0003-9861(59)90090-6.
- Esterbauer H, Cheeseman KH. 1990. Determination of aldehydic lipid peroxidation products: Malonaldehyde and 4-hydroxynonenal. *Methods Enzymol* 186: 407-421. DOI: 10.1016/0076-6879(90)86134-h.
- Etuk IC, Udobang JA, Daniel AO, Ekong O, Okokon JE, Oyepata SJ. 2023a. Effect of leaf extract and fractions of *Solanum anomalum* on oxidative stress markers, kidney function indices and histology of alloxan-induced diabetic rats. *J Curr Biomed Res* 3 (1): 783-799. DOI: 10.54117/jcbr.v3i1.4.
- Etuk IC, Udobang JA, Ebong NO, Okokon JE. 2023b. *Solanum anomalum* leaf extract and fractions attenuate oxidative stress and liver injuries in alloxan-induced diabetic rats. *Biol Med Nat Prod Chem* 12 (1): 33-44. DOI: 10.14421/biomedich.2023.121.33-44.
- Global Burden of Disease (GBD) 2013 Mortality and Causes of Death Collaborators. 2015. Global, regional, and national age-sex specific all-cause and cause-specific mortality for 240 causes of death, 1990-2013: A systematic analysis for the Global Burden of Disease study 2013. *Lancet* 385 (9): 117-171. DOI: 10.1016/S0140-6736(14)61682-2.
- Global Burden of Disease (GBD) Chronic Kidney Disease Collaboration. 2020. Global, regional, and national Burden of Chronic Kidney Disease, 1990-2017: A systematic analysis for the Global Burden of Disease Study 2017. *Lancet* 395 (5): 709-733. DOI: 10.1016/S0140-6736(20)30045-3.
- Gunes FE. 2013. Medical use of squalene as a natural antioxidant. *J Marmara Univ Inst Health Sci* 3 (4): 220-228. DOI: 10.5455/musbed.20131213100404.
- Gupta R, Sharma AK, Dobhal MP, Sharma MC, Gupta RS. 2011. Antidiabetic and antioxidant potential of β -sitosterol in streptozotocin-induced experimental hyperglycemia. *J Diabetes* 3 (1): 29-37. DOI: 10.1111/j.1753-0407.2010.00107.x.
- Injac R, Perse M, Cerne M, Potocnik N, Radic N, Govedarica B, Djordjevic A, Cerar A, Strukelj B. 2009. Protective effects of fullereneol C₆₀(OH)₂₄ against doxorubicin-induced cardiotoxicity and hepatotoxicity in rats with colorectal cancer. *Biomaterials* 30: 1184-1196. DOI: 10.1016/j.biomaterials.2008.10.060.
- Jager KJ, Kovesdy C, Langham R, Rosenberg M, Jha V, Zoccali C. 2019. A single number for advocacy and communication—worldwide more than 850 million individuals have kidney diseases. *Kidney Intl* 96 (5): 1048-1050. DOI: 10.1016/j.kint.2019.07.012.
- James S, Mitchell G. 2006. *Physiology and disorder of water electrolytes and acid base metabolism*. In: Carl AB, Edward R, David E (eds). *Tietz Textbook of Clinical Chemistry and molecular diagnostics*. 4th ed. Elsevier Inc; New Delhi.
- Jha V, Garcia-Garcia G, Iseki K, Li Z, Naicker S, Plattner B, Saran R, Wang AYM, Yang CW. 2013. Chronic kidney disease: Global dimension and perspectives. *Lancet* 382 (9888): 260-272. DOI: 10.1016/S0140-6736(13)60687-X.

- Kalender Y, Yel M, Kalender S. 2005. Doxorubicin hepatotoxicity and hepatic free radical metabolism in rats. The effects of vitamin E and catechin. *Toxicology* 209: 39-45. DOI: 10.1016/j.tox.2004.12.003.
- Kanchan DM, Somani GS, Peshattiwari VV, Kaikini AA, Sathaye S. 2016. Renoprotective effect of diosgenin in streptozotocin induced diabetic rats. *Pharmacol Rep* 68: 370-377. DOI: 10.1016/j.pharep.2015.10.011.
- Khames A, Khalaf MM, Gad AM, Abd El-Raouf OM, Kandeil MA. 2019. Nicorandil combats doxorubicin-induced nephrotoxicity via amendment of TLR4/P38 MAPK/NFj-B signaling pathway. *Chem Biol Interact* 311: 108777. DOI: 10.1016/j.cbi.2019.108777.
- Lakshmi BVS, Sudhakar M. 2010. Protective effect of *Zingiber officinale* on gentamicin-induced nephrotoxicity in rats. *Intl J Pharmacol* 6 (1): 58-62. DOI: 10.3923/ijp.2010.58.62.
- Lawrence RA, Burk RF. 1976. Glutathione peroxidase activity in selenium-deficient rat liver. *Biochem Biophys Res Comm* 71: 952-958. DOI: 10.1016/0006-291x(76)90747-6.
- Leng J, Li X, Tian H, Liu C, Guo Y, Zhang S, Chu Y, Li J, Wang Y, Zhang L. 2020. Neuroprotective effect of diosgenin in a mouse model of diabetic peripheral neuropathy involves the Nrf2/HO-1 pathway. *BMC Compl Med Therap* 20: 126. DOI: 10.1186/s12906-020-02930-7.
- Levey AS, Atkins R, Coresh J, Cohen EP, Collins AJ, Eckardt KU, Nahas ME, Jaber BL, Jadoul M, Levin A, Powe NR, Rossert J, Wheeler DC, Lameire N, Eknoyan G. 2007. Chronic kidney disease as a global public health problem: Approaches and Initiatives - a position statement from kidney disease improving global outcomes. *Kidney Intl* 72 (3): 247-259. DOI: 10.1038/sj.ki.5002343.
- Loeb WF, Quimby FW. 1999. *The Clinical Chemistry of Laboratory Animals*, 2nd ed. Taylor & Francis, Philadelphia, USA.
- Mahmood U, Shukla YN, Thakur RS. 1983. Non-alkaloidal constituents from *Solanum torvum* leaves. *Phytochemistry* 22 (1): 167-170. DOI: 10.1016/S0031-9422(00)80080-1.
- Marklund S, Marklund G. 1974. Involvement of superoxide anion radical in the autooxidation of pyrogallol and a convenient assay for superoxide dismutase. *Eur J Biochem* 47: 469-474. DOI: 10.1111/j.1432-1033.1974.tb03714.x.
- Micera M, Botto A, Geddo F, Antoniotti S, Berteau CM, Levi R, Gallo MP, Querio G. 2020. Squalene: More than a step toward Sterols. *Antioxidants* 9: 688. DOI: 10.3390/antiox9080688.
- Mohan M, Kamble S, Gadhi P, Kasture S. 2010. Protective effect of *Solanum torvum* on doxorubicin-induced nephrotoxicity in rats. *Food Chem Toxicol* 48 (1): 436-440. DOI: 10.1016/j.fct.2009.10.042.
- Offor SJ, Ubengama EE. 2015. Phytochemical and antidiabetic studies of ethanolic extracts and fractions of the fruits of *Solanum anomalum* Thonn. *Ex. Schumach. Intl J Sci Res Educ* 3 (9): 4343-4350. DOI: 10.18535/IJSRE/V2I9.06.
- Offor SJ, Nwokocho C, Mbagwu HOC, Orisakwe OE. 2021. Hepato-renal effect of *Solanum anomalum* Thonn. *Ex. Schumach. Intl J Sci Res Educ* 3 (9): 4343-4350. DOI: 10.18535/IJSRE/V2I9.06.
- Okokon JE, Davies K, Lekara J, Iwara K, Thomas P, Li WW. 2022a. Antidiabetic and hypolipidemic activities of solvents fractions of *Setaria megaphylla* and its phytochemical characterisation. *Phytomed* Plus 2: 100182. DOI: 10.1016/j.phyplu.2021.100182.
- Okokon JE, Davis K, Azare BA. 2015. Antimalarial activity of *Breynia nivosa*. *J Herb Drug* 5 (4): 168-172.
- Okokon JE, Davis K, Umoh EE, Amazu LU 2017b. Antiinflammatory activity of leaf extract of *Solanum anomalum*. *J Herb Drug* 7 (4): 243-249.
- Okokon JE, Etuk IC, Thomas P, Drijfhout FP, Claridge TM, Li WW. 2022b. In vivo antihyperglycaemic and antihyperlipidemic activities and chemical constituents of leaf extract and fractions of *Solanum anomalum* in alloxan-induced diabetic rats. *Biomed Pharmacother* 151: 113153. DOI: 10.1016/j.biopha.2022.113153.
- Okokon JE, Nyong EE, Obot J, Davies K. 2019b. Anticonvulsant and depressant activities of ethanol leaf extract of *Solanum anomalum*. *Nig J Pharm Appl Sci Res* 8 (1): 73-79.
- Okokon JE, Nyong EE, Thomas PS, Udoh AE. 2019a. Antioxidant and antiulcer activities of ethanol leaf extract and fractions of *Solanum anomalum*. *Discover Phytomed* 6 (2): 20-25. DOI: 10.15562/phytomedicine.2019.79.
- Okokon JE, Okokon PJ, Sahal D. 2017a. In vitro antiplasmodial activity of some medicinal plants from Nigeria. *Intl J Herb Med* 5 (5): 102-109.
- Okokon JE, Opara KN, Azare B. 2016. Antimalarial activity of *Solanum anomalum* (Solanaceae). *Nig J Pharm Appl Sci Res* 5 (1): 1-6.
- Okokon JE, Udoh AE, Nyong EE, Amazu LU. 2020. Analgesic activity ethanol leaf extract of *Solanum anomalum*. *Afr J Pharmacol Ther* 9 (1): 22-26.
- Olorundare OE, Adeneye AA, Akinsola AO, Sanni DA, Koketsu M, Mukhtar H. 2020. *Clerodendrum volubile* ethanol leaf extract: A potential antidote to doxorubicin-induced cardiotoxicity in rats. *J Toxicol* 2020: 8859716. DOI: 10.1155/2020/8859716.
- Rajasekaran M. 2019. Nephroprotective effect of *Costus pictus* extract against doxorubicin-induced toxicity on Wistar rat. *Bangladesh J Pharmacol* 14: 93-100. DOI: 10.3329/bjp.v14i2.39992.
- Rashid S, Ali N, Nafees S, Ahmad ST, Arjumand W, Hasan SK, Sultana S. 2013. Alleviation of doxorubicin-induced nephrotoxicity and hepatotoxicity by chrysin in Wistar rats. *Toxicol Mech Methods* 23: 337-345. DOI: 10.3109/15376516.2012.759306.
- Rehman MU, Tahir M, Khan AQ, Khan R, Hamiza OO, Lateef A, Hassan SK, Rashid S, Ali N, Zeeshan M, Sultana S. 2014. D-limonene suppresses doxorubicin-induced oxidative stress and inflammation via repression of COX-2, iNOS, and NFjB in kidneys of Wistar rats. *Exp Biol Med* (Maywood) 239: 465-476. DOI: 10.1177/1535370213520112.
- Rhee CM, Kovesdy CP. 2015. Epidemiology: Spotlight on CKD deaths-increasing mortality worldwide. *Nat Rev Nephrol* 11 (1): 199-200. DOI: 10.1038/nrneph.2015.25.
- Rhetso T, Shubharani R, Roopa MS, Sivaram V. 2020. Chemical constituents, antioxidant, and antimicrobial activity of *Allium chinense* G. Don. *Future J Pharm Sci* 6: 102. DOI: 10.1186/s43094-020-00100-7.
- Saran R, Robinson B, Abbott KC, Bragg-Gresham J et al. 2020. US Renal Data System 2019 Annual Data Report: Epidemiology of Kidney Disease in the United States. *Am J Kidney Dis* 75 (1): A6-A7. DOI: 10.1053/j.ajkd.2019.09.003.
- Sengupta S, Nandi I, Bhattacharyya DK, Ghosh M. 2018. Antioxidant and anti-bacterial properties of 1-Octacosanol isolated from rice Bran Wax. *J Plant Biochem Physiol* 6: 206. DOI: 10.4172/2329-9029.1000206.
- Sinha AK. 1972. Colorimetric assay of catalase. *Anal Biochem* 47: 389-394. DOI: 10.1016/0003-2697(72)90132-7.
- Susantitaphong P, Cruz DN, Cerda J, Abulfaraj M, Alqahtani F, Koulouridis I, Jaber BL. 2013. World incidence of AKI: A meta-analysis. *Clin J Am Soc Nephrol* 8 (9): 1482-1493. DOI: 10.2215/CJN.00710113.
- Udobang J, Okokon JE, Ukpang BD, Akpan SJ. 2022. Analysis of ethanol extract of *Solanum anomalum* leaves for antidiarrhoeal activity. *J Curr Biomed Res* 2 (2): 145-157. DOI: 10.54117/jcbr.v2i2.11.
- Yilmaz S, Atessahin A, Sahna E, Karahan I, Ozer S. 2006. Protective effect of lycopene on adriamycin-induced nephrotoxicity and nephrotoxicity. *Toxicology* 218: 164-171. DOI: 10.1016/j.tox.2005.10.015.
- Yuan-Yuan LU, Jian-Guang LU, Ling-Y K. 2011. Chemical constituents from *Solanum torvum*. *Chin J Nat Med* 9 (1): 30-32. DOI: 10.1016/S1875-5364(11)60015-0.